

Age Related Macula Detection Using Trimmed Median Filter (TMF)

Shanti¹, C Girishkumar², Md Rizwan³
^{1,2,3}ECE Department, Sreedattha Institute Of Engineering & Science

ABSTRACT: The Age-related macular degeneration (AMD) is a deterioration or breakdown of the eye's macula. The macula is a small area in the retina, the light-sensitive tissue lining the back of the eye that is responsible for your central vision, allowing you to see fine details clearly. Most important part of the retina for human vision is fovea. The destruction of delicate cones of fovea causes the person to become blind. The size of fovea zone in fundus eye image is related to various diseases that lead to blindness. Usually a circle of radius 200 micron is approximately the zone of fovea. If the radius is smaller then it may be an indication of an infection of the eye that may lead to disease. The radius of the fovea region is also an indication of the stages of retinopathy. This paper compares the cases where the images are exposed to two types of noises like salt and pepper and Gaussian noise. De noising using two different filters namely adaptive wavelet filter and Modified Decision Based Unsymmetrical Trimmed Median Filter (MDBUTMF). The two methods are compared on the basis of PSNR values. The proposed method is used to carry out general-purpose method for detecting the Fovea region of noisy images. Then using Mathematical Morphology the blood vessel and hence the fovea region is found. Publicly available DRIVE database of 250 people was taken with different eye problems are analyzed and the proposed filter filter outperform the excising methodology. Matlab 7.5 tool box was used to analyze the result.

Keywords: Age-related macular degeneration (AMD), Median Filter (MF), Fundus, Unsymmetric Trimmed Median Filter (UTMF), Alpha Trimmed Mean Filtering (ATMF), Modified Decision Based Unsymmetrical Trimmed Median Filter (MDBUTMF)

I. INTRODUCTION

The Macular Degeneration is the leading cause of vision loss, more than cataracts and glaucoma combined. It is considered an incurable eye disease, Fovea is the most fundamental aspect of retina. It is located in the centre of the macula, which is the darkest part approximated by a circle. Geometrically Fovea is located at a distance of 2.5 times the diameter of Optic Disk from its centre. Since Fovea is very crucial to the retina, any damage to its delicate cones may cause retinopathy or permanent blindness. Its Zone is approximately a circle of radius 200 microns, and since its size is directly related to the retina; any smaller radius than which is intended may cause the above kinds of damage. Due to its non detection, retinal disease occur and there are a lack of trained ophthalmologists to handle automation procedure, and who are able to focus on the Fovea.

1.1. Stages of Age-related Macular Degeneration

The Dry Stage

This is the more common form. In this type of AMD, the delicate tissues of the macula become thinned and slowly lose function over a period of years to decades.

The Wet Stage

This is less common, but is typically more damaging. The wet type of AMD is caused by the growth of abnormal blood vessels behind the macula. The abnormal blood vessels tend to hemorrhage or leak fluid, resulting in the formation of scar tissue if left untreated. In most instances, the wet stage develops in addition to the dry stage of AMD. AMD develops differently in each person and the symptoms tend to vary. AMD may cause a progressive loss of central sight. However, it does not usually cause total blindness. Peripheral vision is unaffected, allowing a certain amount of mobility in normal surroundings. If left untreated, the wet type of AMD may progress rapidly.

1.2 Symptoms Blurry vision

- Distorted vision
- Straight lines appear wavy
- Objects may appear as the wrong shape or size
- The loss of clear, correct colors

- Difficulty reading
- A dark, empty area in the center of vision

Many researches are conducted in order to analyze the Fovea. Sinthanayothin[1] have conducted study using template size 40x40 with Gaussian distribution is around 2.2, that is the measurement of maximum correlation coefficient between template and intensity image to identify the location of the Fovea. Another study was conducted by chutatape[2] based on parabola fitting concerning the main blood vessels. Martinez[3] proposed a method based on Parabola fitting on the main blood vessels. In fact the identification of the blood vessel is an acute factor in order to locate and analyze about the Fovea.

II. METHODOLOGY

The process involved are

1. Unsymmetrical Trimmed Median Filter
2. Blood Vessel Segmentation
3. Localization Of Fovea Region
4. Fovea Detection

2.1 Symmetric Trimmed Median Filter

Trimmed filter is to reject the noisy pixel from the selected 3x3 window. A symmetrical filter called Alpha Trimmed Mean Filtering (ATMF) is used where the trimming is symmetrical in either end. In this method, even the uncorrupted pixels are also trimmed. This may lead to loss of image details and may end up blurring the image. This drawback is over come by an Unsymmetric Trimmed Median Filter (UTMF) is used. In this UTMF, the selected 3x3 window elements are arranged in either increasing or decreasing order. Then the pixel values 0's and 255's in the image (i.e., the pixel values responsible for the salt and pepper noise) are removed from the image. Then the median value of the remaining pixels is used. This median value is used to replace the noisy pixel. This filter is called trimmed median filter because the pixel values 0's and 255's are removed from the selected window. This method is superior than ATMF in removing noise.

$$psnr \text{ in } dB = 10 \log_{10}(255^2/MSE) \quad (1)$$

$$MSE = (\sum_i \sum_j (y(i,j) - \hat{y}(i,j))) / m \times n \quad (2)$$

2.1.1 Blood Vessel Segmentation. Blood vessels segmentation blood of the retinal images allows early diagnosis of disease; automation of this process provides various benefits including minimizing subjectivity and eliminating a painstaking, tedious task. Previous approaches, require some more changes that can take the case of abnormal retinal images. We propose to utilize a median filtering scheme to carry out demising of the image and thereby to find the fovea of the retina. Examination of blood vessels in the eye allows detection of eye diseases such as glaucoma and diabetic retinopathy. Traditionally, the vascular network is mapped by hand in a time-consuming process that requires both training and skill. Automating the process allows consistency, and most importantly, frees up the time that a skilled technician or doctor would normally use for manual screening. For instance, popular convolution approaches suffer from variable retinal background and low contrast between vessels and surrounding pixels. Tracking algorithms fail in special cases on abnormal images; they are often sidetracked by light objects and sometimes experience difficulty locating starting points. Current levels of success are still frequently inadequate for wide scale implementation. Our method utilizes Modified Decision Based Unsymmetrical Trimmed Median Filter (MDBUTMF) to remove salt and pepper noise, enhance the image. To find its performance over noise, we can add some salt and pepper noise. After this, we calculated the peak signal to noise ratio. Performing basic morphological operation to find the blood vessels of the eyes

2.2 Localization Of Fovea Region

The fovea is localized by detection of blood vessels. In this method the scheme relies on information regarding optical disk (OD). Thus it becomes necessary to detect OD. In this method, the perfection in detection is not very essential as it deals with certain average global information of the disk. Some of the previous used schemes used Gaussian matched filter to find the direction of the main blood vessels and then thinning and filtering of the segmented main blood vessels is carried out to represent the OD center. Hajer et al[7]. uses Water-snake to localize the OD [7].

The method to determine the center and contour of the optic disk using basic mathematical morphology is adopted in this paper. Once the identification of major blood vessels are carried out, an iterative algorithm is used to find out the position of OD which is in the either side of the image. Then the centroid of the blood vessels is calculated. A reference line will be the vertical line through the centroid. Removal of the vessels located in the temporal side (opposite side) of OD and beyond the reference line is carried. Retained vessels are

skeletonized and pruned to obtain the parabola shaped vessel. The point where the horizontal line passes through the centroid and parabola denoting the vessel intersecting each other is taken as the center of OD. The OD contour is determined by using Watershed transformation with internal and external markers. Obtaining the center and contour of the optic disk, the diameter of the disk can be easily calculated. To localize the fovea region, we start with the image, containing only the blood vessels. Let, P be the approximated center of the OD, Q be the point on the horizontal line passing through the center at a distance in the direction of centroid. P lies in the vicinity (may be above/below/within) of the macula region. In order to extract the fovea region, a strip of width k pixels through the point Q (take Q as middle of the strip) in a direction perpendicular to the line GP is considered. We consider on the fact that the fovea region is free from any vessel. A sliding window of size $k \times k$ is applied along the strip starting from point Q in upward and down ward direction. An array of number is obtained where the number denotes the occurrence of black pixels lying in the window. Finally, the maximum run length of zeros in the array enables us to localize the fovea region. In our experiment k is taken as nine.

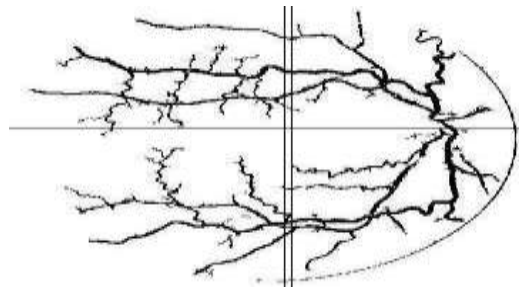


Fig.1 Horizontal line and vertical strip of blood vessel segmented image

2.3 Fovea detection

Fovea is the most essential part of the retina for human vision. If the delicate cones of our fovea are destroyed the person may become blind. The size of fovea zone in fundus eye image determines whether it may lead to various diseases, which may turn out to blindness. Fovea is characterized by the center of the macula. In fundus retinal image the macula is the darkest part approximated by a circle. Geometrically fovea is at a distance 2.5 times the diameter of the Optic Disk (OD) from its center.

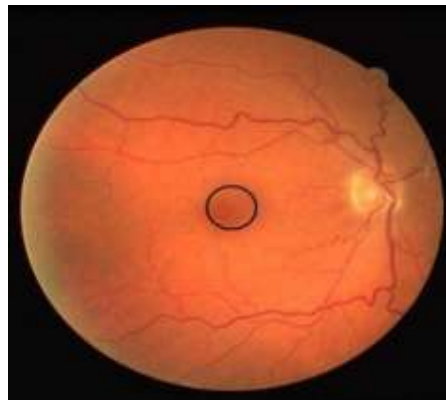


Fig.2 Retinal fundus image showing fovea region

Various attempts were made for the successful detection of fovea region. Algorithm steps are:

Input: Color fundus Retinal image.

Output: Image containing Fovea region.

Step 1 Take retinal fundus colour image.

Step 2 a To show the performance over noise, add some AWGN noise use adaptive wavelet filter

Step 2 b To show the performance over noise, add salt and pepper noise and use modified filter Modified Decision based Unsymmetrical Trimmed Median Filter (MDBUTMF)

Step 3 Comparison of the two types of filtering based on peak signal to noise ratio

Step 4 Apply preprocessing steps such as RGB to Gray scale conversion and contrast enhancement .

Step 5 Apply morphological opening operation to reduce the small noise.

Step 6 Apply morphological closing operation to remove the vessels structure.

Step 7 Apply Top-Hat transformation for extracting the vessels like structure.

- Step 8 Binarize the resultant image by thresholding.
- Step 9. Locate a point Q horizontally at a distance 2.5 d from P towards the centre where G the centre and d, the diameter of optical disc.
- Step 10 Consider a vertical strip of width k pixels around Q perpendicular to GP.
- Step 11 Obtain R as the portion of the gray-scale image, I corresponding to the black region.
- Step 12 Binarize R to approximate macula region.
- Step 13 Refine binarized R by removing noise and fitting the circle to obtain macula region.
- Step 14 Detect fovea region as the small area around center of macula.

III. IMPLEMENTATION AND RESULTS.

First general approach is used for detecting the Fovea region of high noise document images. In preprocessing the images from the drive images are taken as the original image. Matlab tool box 7.5 was used. coding is written and tested. Using the filter Modified Decision Based Unsymmetrical Trimmed Median Filter (MDBUTMF) for noise removal was carried out.

Using wavelet filter the same procedure was adapted. The performance of this type of filtering is compared with adaptive wavelet filter on the basis of peak signal to noise ratio. Total noise variance and the PSNR measurements are taken. The noise images for both the method are measured and the performance measure was plotted as bar chart and a graph. 25 samples are tested and analysed and only 5 results are shown below

Noise insensitive fovea detection of five sets of fundus images




Fig. 3 a) original image b) noisy image c) denoised image d) gray image e) opening operation f) closing operation g) Top Hat h) vessel segmentation i) blood vessel mark image j) detected Fovea

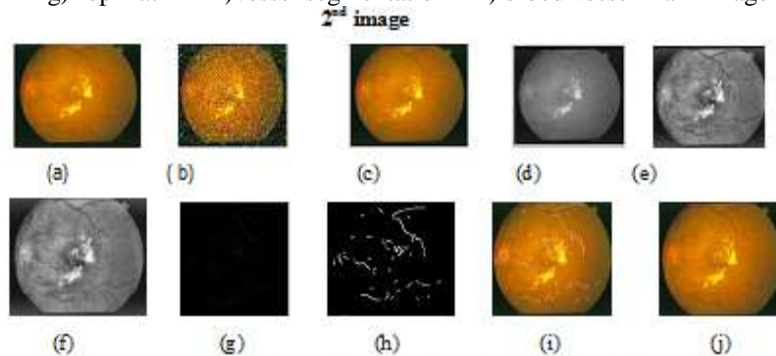


Fig. 4 a) original image b) noisy image c) denoised image d) gray image e) opening operation f) closing operation g) Top Hat h) vessel segmentation i) blood vessel mark image j) detected Fovea

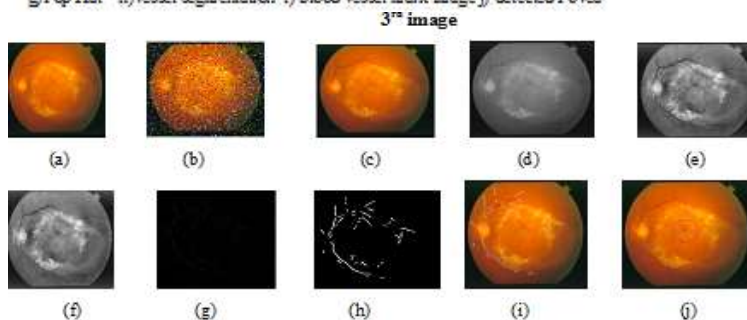


Fig. 5 a) original image b) noisy image c) denoised image d) gray image e) opening operation f) closing operation g) Top Hat h) vessel segmentation i) blood vessel mark image j) detected Fovea

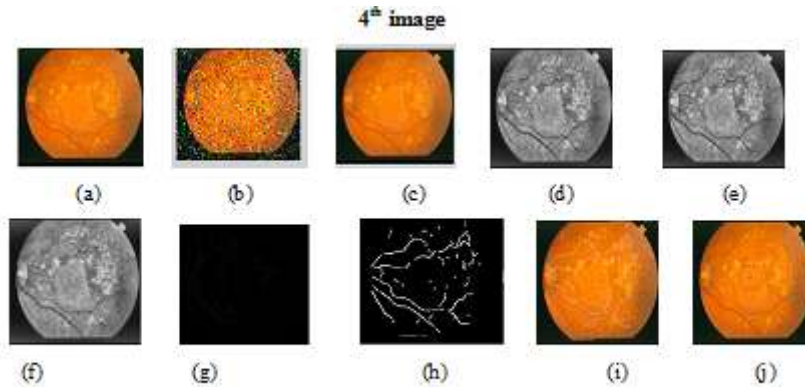


Fig.6 a) original image b) noisy image c) denoised image d) gray image e) opening operation f) closing operation g)Top Hat h) vessel segmentation i) blood vessel mark image j) detected Fovea

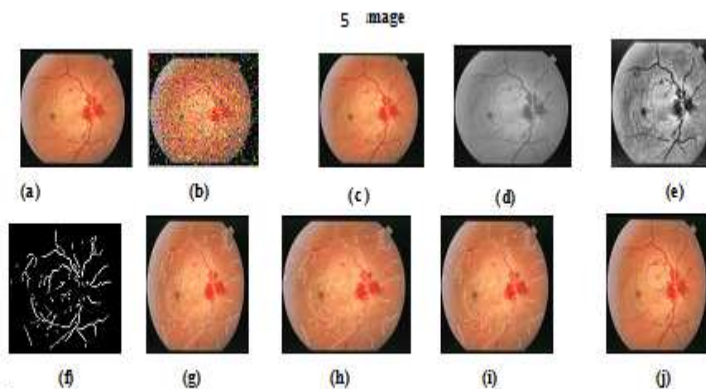


Fig.7 a) original image b) noisy image c) denoised image d) gray image e) opening operation f) closing operation g)Top Hat h) vessel segmentation i) blood vessel mark image j) detected Fovea

Performance comparison for the noise image with total noise variance and with the excising method and the proposed method are shown in fig 8a) with Red, green blue colors .

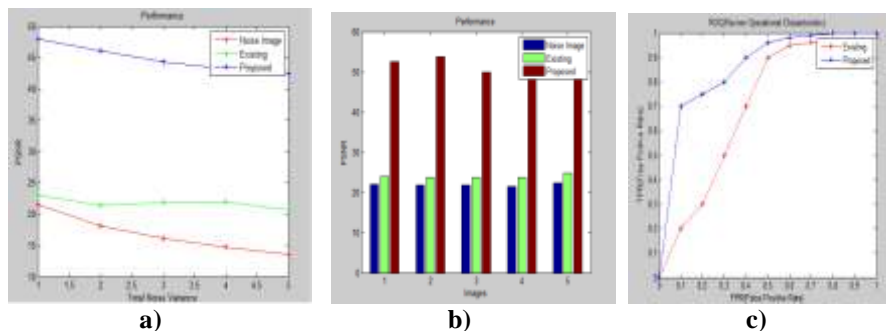


Fig 8.a) Graph showing total noise variance vs PSNR b) graph showing images vs PSNR c) Graph showing FPR vs TPR

Fig 8. b) graph showing images vs PSNR with the noise image existing method and the proposed method. Note the PSNR with the proposed method is able to remove the noise more than the existing method. Performance comparison False positive rate (FPR) with true positive rate (TPR) is drawn for the excising method and the proposed method and it was shown in Fig 8. c) showing FPR vs TPR

IV. CONCLUSION

A conclusion from the measurement the graph it was observed that the MDBUMF out performs than wavelet filters in the fully affected case. Hence MDBUTMF is used to find the fovea of the eye using simple and fast algorithm using Mathematical Morphology. Proposed algorithm is based on the structure of the blood vessels and little bit information of the optic disk. We tested our result on a publicly available DRIVE database

and got a comparable result with a state of the art in this area. We tested our proposed algorithm on a publicly available DRIVE database [8]. The database contains 250 images of size 565 * 584. The scheme has detected fovea correctly in all images i.e., the success rate is two fold. We tested and find fovea region in all 50 images having 3 categories one with not affected case, 50 % problem case and 100 % affected cases. Thus, few sample results on DRIVE data base shows the color fundus images, the blood vessels of the images corresponding image along with the horizontal line and vertical strip. 100% results are achieved with fovea fully affected cases but still further investigation needed on the Non affected cases.

REFERENCES

- [1]. Akkerkar, R. A Mohammad Saleh Miri And Ali Mahloojifar, "Retinal Image Analysis Using Curvelet Transform And Multistructure Elements Morphology By Reconstruction", Ieee Transactions On Biomedical Engineering, Vol. 58.
- [2]. O.Chutatape, "Fundus Foveal Localization Based On Vessel Model," In Proceedings Of The 28th Ieee Embs Annual International Conference New York City, Usa, 2006, Pp. 4440-4444
- [3]. M. E. Martinez-Perez, A. D. Hughes, S. A. Thom, And K. H. Parker "Improvement Of A Retinal Blood Vessel Segmentation Method Using The Insight Segmentation And Registration Toolkit (ITK)," In Proc. IEEE 29thannu. Int. Conf. EMBS. Lyon, IA, France, 2007, Pp. 892-895.4S.
- [4]. Dua, N. Kandiraju, And H.W. Thompson, "Design And Implementationof A Unique Blood-Vessel Detection Algorithm Towards Early Diagnosis Ofdiabetic Retinopathy," In Proc. IEEE Int. Conf. In Inf. Technol.
- [5]. A.M.Mendonc,A And A. Campilho, "Segmentation Of Retinal Blood Vesselsby Combining The Detection Of Centerlines And Morphological Reconstruction,"IEEE Trans. Med. Imag., Vol. 25, No. 9, Pp. 1200-1213, Sep. 2006.
- [6]. M. Foracchia, E. Grisan, And A. Rugger (2004) "Detection Of Optic Disc In Retinal Images By Means Of A Geometrical Model Of Vessel Structure,"IEEE Transactions On Medical Imaging, Vol. 23, No. 10, Pp. 1189-1195
- [7]. J. Hajer, H. Kamel, And E. Nouredine (2008) "Localization Of The Optic Disk In Retinal Image Using The Watersnake," In Proceedings Of The International Conference On Computer And Communication Engineering, Pp. 947-951.
- [8]. M.V.Ibaez And A. Sim (1999) "Bayesian Detection Of The Fovea In Eye Fundus Angiographies," Pattern Recognition Letters, Vol. 20, Pp. 229-240
- [9]. C. Sinthanayothin, J. F. Boyce, H. L. Cook, And T. H. Williamson (1999) "Automated Localisation Of The Optic Disc, Fovea, And Retinal Blood Vessels From Digital Color Fundus Images," Br. Journal Of Ophthalmol, Vol. 83
- [10]. Chaudhuri, S. Chatterjee, N. Katz, M. Nelson, And M. Goldbaum, "Detection Of Blood Vessels In Retinal Images Using Two-Dimensional Matched filters," IEE Transactions On Medical Imaging, Vol. 8, No. 3, Pp 263-269, 1989.
- [11]. B. Al-Diri, A. Hunter, And D. Steel, "An Active Contour Model For Segmenting And Measuring Retinal Vessels" IEEE Transactions On Medical Imaging, Vol. 24, No.9, Pp. 1488-1497, 2009.
- [12]. F. Zana And J.-C. Klein, "Segmentation Of Vessel-Like Patterns Using Mathematical Morphology And Curvature Evaluation," IEEE Transaction Son Medical Imaging, Vol. 10, No. 7, Pp. 1010-1019, 2001.
- [13]. J. Staal, M. D. Abramoff, M. Niemeijer, M. A. Viergever, And B. Vanginneken, "Ridge-Based Vessel Segmentation In Color Images Of The Retina," IEEE Transactions On Medical Imaging, Vol. 23, No. 4, Pp.-509, 2004.